



## Effective High Grade Cervical Intraepithelial Neoplasia Case Finding in Low Resource Settings

Nafiseh Faghih<sup>1</sup>, Maliheh Arab<sup>1\*</sup>, Afsaneh Tehranian<sup>2</sup>, Behnaz Ghavami<sup>2</sup>, Behnaz Nouri<sup>1</sup>, Donya Khosravi<sup>3</sup>

Received: 8 Jun 2021

Published: 11 Apr 2022

### Abstract

**Background:** Visual Inspection with Acetic Acid (VIA) is an inexpensive option for cervical cancer screening. In this study, we evaluated the role of the VIA as well as of the clinical symptoms/signs to find the best case-finding method for Cervical Intraepithelial Neoplasia (CIN) 2+.

**Methods:** In a cross-sectional study, we extracted from records the demographic characteristics, clinical symptoms/signs, and indications for colposcopy referral of patients with CIN 2+ in pathology. Patients were divided into 1- Abnormal Pap smear, 2- Positive VIA, 3- abnormal Pap smear with clinical symptoms/signs, 4-VIA positive with clinical symptoms/signs, 5- only clinical symptoms/signs. The sensitivity of each method was studied to determine their effectiveness as a screening method.

**Results:** Out of 146 patients who underwent colposcopy, 38 patients had it due to abnormal Pap smears, 37 due to positive VIA, 21 due to abnormality of both these tests, and 50 due to clinical symptoms/signs despite having normal screening tests. The sensitivity for VIA and Pap smear was 73.39% (17.48%-83.31%) and 40.41% (32.47%-48.86%) respectively. Presence of at least one of the three clinical symptoms/signs and a positive VIA found 78.8% of CIN 2+ cases. Presence of at least one of the three clinical symptoms/signs and abnormal Pap smear identified 84.2% of the cases.

**Conclusion:** To find high-grade CIN, focused attention to the clinical symptoms/signs, even in the presence of normal Pap smear, can increase the sensitivity of Pap smear and VIA. In low resource settings, a simple, highly sensitive method like VIA can be used in addition to or as an alternative to other means.

**Keywords:** Visual Inspection with Acetic acid, Cervical Intraepithelial Neoplasia, Symptom, Sensitivity, Papanicolaou Test, VIA

**Conflicts of Interest:** None declared

**Funding:** The project is funded by Shahid Beheshti University.

\*This work has been published under CC BY-NC-SA 1.0 license.

Copyright© Iran University of Medical Sciences

**Cite this article as:** Faghih N, Arab M, Tehranian A, Ghavami B, Nouri B, Khosravi D. Effective High Grade Cervical Intraepithelial Neoplasia Case Finding in Low Resource Settings. *Med J Islam Repub Iran.* 2022 (11 Apr);36:33. <https://doi.org/10.47176/mjiri.36.33>

### Introduction

Cervical cancer is considered a very important threat to women's health. The economic and psychological burden of the disease not only affects the people suffering from it but also impacts the society and economy (1). It is considered to be the fourth most common malignancy in women worldwide, while in women of Africa and East

Asia regions, it ranks second (2). Cervical Cancer was named by WHO to be the biggest threat to women's lives. In 2018, nearly 570,000 new cases were identified globally, over 85% of which were recorded in low and middle-income countries (3). Worldwide, approximately 311,000 women died of cervical cancer in 2018 (4). By

**Corresponding author:** Dr Maliheh Arab, [drmarab@sbmu.ac.ir](mailto:drmarab@sbmu.ac.ir)

<sup>1</sup> Department of Gyneco-Oncology, School of Medicine, Shahid Beheshti University of Medical Sciences, Tehran, Iran

<sup>2</sup> Department Obstetrics and Gynecology, School of Medicine, Tehran University of Medical Sciences, Tehran, Iran

<sup>3</sup> Department Obstetrics and Gynecology, School of Medicine, Kermanshah University of Medical Sciences, Kermanshah, Iran

#### ↑ What is "already known" in this topic:

Screening methods for early detection of pre-invasive lesions of cervix are an effective means of reducing Cervical cancer burden. Visual Inspection of Acetic acid is an alternative, inexpensive test which can be performed in any setting including in resource-limited areas.

#### → What this article adds:

Sensitivity of VIA in our study was estimated to be 73.39%. we concluded that in high grade cervical lesions case finding, attention to three clinical symptoms/signs (abnormal cervix, abnormal bleeding and chronic vaginal discharge), even in the presence of normal Pap smear, is of great importance and by using them, we can increase the sensitivity of Pap smear and VIA.

2030, the incidence of the disease is expected to rise from 57,000 to 700,000 cases annually (5).

In a study in Golestan province, Iran, conducted between 2004 and 2010, cervical cancer was found to be the second commonest gynecological malignancy after ovarian cancer (6). In Iran, the disease was found to have an average age-standardized incidence (ASR) of 2.5 per 100,000 and age-standardized mortality (ASMR) of 1.04 per 100,000 in 2012 (7).

The capability of communities in preventing this malignancy and decreasing its incidence rate has been recognized as one of the community health indicators. In this regard, screening methods for early detection of pre-invasive lesions (i.e., cervical intraepithelial neoplasia (CIN)) are an effective means of reducing the disease burden. Fortunately, many of the etiological factors for the disease are identified and in addition, the incidence of the disease has been reduced effectively by the use of the HPV vaccine (1).

Given its long pre-invasive stage, cervical cancer is considered to be a preventable disease. Screening, identification, and treatment of cervical lesions in their pre-invasive stage has been greatly facilitated by the use of cervical cytology, but despite preventability of the disease, in 2014, CDC reported 12578 new cases of cervical cancer in the United States with disease mortality of 4115 cases that year (8). Lack of participation in screening programs was a factor observed in most of the new cases (9).

Different screening methods have been developed for cervical cancer, namely: gross cervical screening, Visual Inspection with Acetic acid (VIA) testing, Pap smear, Human papilloma virus (HPV) testing, and a combination of the last two tests, known as CO-TEST. In developing countries, a prevention rate of around 70% has been achieved with the use of a general screening plan which included referral of eligible individuals along with the recall of the positive cases (4).

Cytological examination of extracted cervical cells resulted in a significant reduction of incidence of cervical cancer. Pap smear has reportedly been 51% sensitive in diagnosing pre-invasive cervical lesions, with an associated 49% false-negative rate. Due to the inability to obtain enough cells from the lesion or when the lesion is very small, sampling errors do occur (9).

VIA is an alternative, inexpensive test which can suitably be performed in any setting, including in resource-limited areas. In VIA, 3-5% acetic acid is applied to the cervix for 60 seconds, after which the cervix is visually examined for the presence of Aceto-White lesions. Identification of these lesions is regarded as a positive test (10). Various studies have described different sensitivities for this test, ranging from 71 to 91 percent. VIA is stated as being 68.5-74% specific with the estimated accuracy of about 77% (11, 12). VIA has been introduced into the cervical screening recommendations by World Health Organization (WHO) and given its convenience and low cost. It's recommended as one of the initial tests to be used for this purpose (5).

HPV is another cervical screening method, the samples

of which can be collected either by the individual or by health care workers. In a study conducted in China in 2001, the HPV test was compared to other testing methods. The study found HPV self-testing to be 95% sensitive and 98% specific for CIN 2+ lesion detection, while the reported sensitivity and specificity of VIA were 71% and 74% respectively (12).

Clinical symptoms of pre-invasive cervical lesions include abnormal bleeding (i.e., post-coital and post-menopausal bleeding), vaginal discharge, pelvic pain, etc. Even with normal screening test results, the presence of these symptoms should warrant more careful and thorough evaluation.

In this study, we decided to examine the different methods to find CIN 2 and higher-grade lesions and assess the importance and success of these methods in the identification of these lesions.

### Methods

This is a descriptive cross-sectional study of 146 patients referred to the gynecologic oncology clinic of the Imam Hossein Hospital, Tehran, in the period of 2009-2018, and at the discretion of Gyne-oncologist, underwent colposcopy and biopsy, the pathology result of which confirmed CIN 2 and above. This medical center is a public tertiary oncology ward referral of the southeastern area of Tehran. All referred cases were included in the study. After obtaining patients' consent, demographic information and data about the indication of colposcopy were extracted from their records and entered into questionnaires. Cases with insufficient information, unwillingness to enter the study, and pregnant women were excluded. Based on the recorded history and examination, patients' clinical manifestations (symptoms/signs) were identified and recorded. Clinical signs & symptoms which were taken into account included: abnormal bleeding, chronic vaginal discharge (more than 2 months based on patient history), and abnormal shape of the cervix. Evidence of cervical hypertrophy and cervical erosion with contact bleeding were classified as abnormal cervical appearance. Patients were classified into different groups based on the screening method used to indicate colposcopy in them: namely: VIA, Pap smear and the clinical manifestation/s. The frequency and sensitivity of each of these in the detection of CIN 2+ lesions were evaluated.

### Statistical methods

Description of quantitative data was done by mean and standard deviation, and for qualitative data, it was done by frequency and percentage. To measure the diagnostic value of each method in the screening, their sensitivity and confidence interval were calculated. The Chi-squared test was used to compare ratios. A significance level of 0.05 was considered. SPSS software was used to analyze the data.

### Results

In the present study, 146 women with high-grade intraepithelial cervical lesions were studied. The mean age of

patients was  $40.28 \pm 10.93$  years. The lowest and highest age of patients were 20 and 73 years, respectively. The average gravidity was  $2.52 \pm 1.99$ . The average age at marriage was  $20.5 \pm 5.21$ .

A total of 115 out of 146 subjects (78.8%) showed clinical manifestations (symptoms/signs) of the disease, including at least one of the three findings, namely: abnormal cervical appearance, abnormal bleeding (all types), and chronic vaginal discharge. Of these findings, 48.6% of patients had only one finding, while 30.1% of individuals had two or more (Fig. 1). The most common symptoms/signs among women with clinical findings were the abnormal shapes of the cervix on examination (52.7%) followed by chronic vaginal discharge (32.2%) and abnormal uterine bleeding (AUB) (32.2%). The commonest type of AUB was post-coital bleeding (PCB) with a frequency of 17.8% (Table 1).

The number of clinical symptoms/signs did not have a statistically significant relationship to the type of pathology.

The most common abnormal Pap smear pathology was Atypical squamous cells of Undetermined Significance (ASCUS), seen in 19.2% of patients, followed by High-

grade Squamous Intraepithelial Lesions (HSIL) (8.9%) and Low-grade Squamous Intraepithelial Lesions (LSIL) (6.2%). The prevalence of Atypical Squamous Cells: cannot exclude High-grade (ASCH) and Atypical Glandular Cells (ACG) was 3.4% and 2.7%, respectively (Table 2). The pathology was CIN 2 in 68 cases and CIN 3 in 78 cases. On colposcopic evaluation, all individuals had Aceto-White areas.

A total of 21 (14.4%) patients had positive VIA as well as abnormal Pap smears, of whom 16 (76.2%) were symptomatic. Comparing the symptomatic and asymptomatic groups, the sensitivity of high-grade lesion detection was higher in the symptomatic group ( $p=0.002$ ).

Thirty-eight patients (26%) had only an abnormal Pap smear, of whom 21 (55.3%) were symptomatic; in comparing the symptomatic and asymptomatic groups with abnormal Pap smears, the sensitivity of this test for detection of CIN 2+ lesions was significantly higher in the symptomatic group ( $p=0.010$ ).

Of the studied patients, 37 (25.4%) had only positive VIA, of whom 28 (75.7%) were symptomatic; here also, the higher test sensitivity in the symptomatic group was obvious ( $p<0.001$ ).

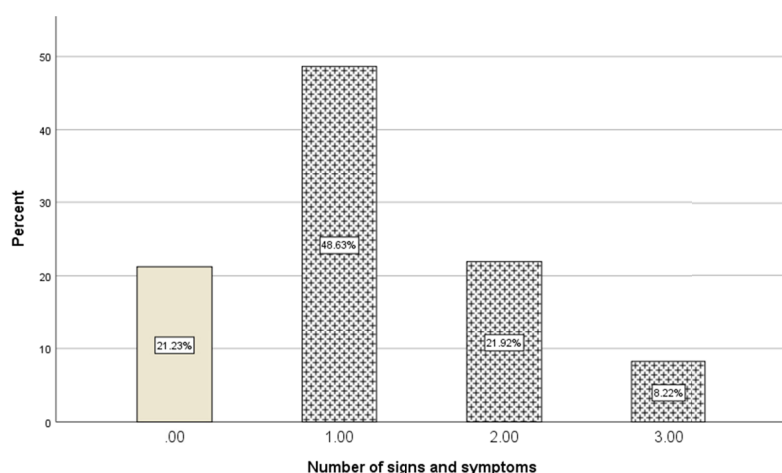


Fig. 1. Distribution of number of symptom/sign in our study patients

Table 1. Distribution of symptom/sign in symptomatic patients

Symptom	Frequency	Percent
AUB <sup>‡</sup>	47	32.2
IMB	11	7.5
HMB	9	6.2
PMB	12	8.2
PCB	26	17.8
Irregular bleeding	5	3.4
Abnormal cervical shape	77	52.7
Vaginal discharge	47	32.2

AUB: abnormal uterine bleeding, HMB: heavy menstrual bleeding, IMB: interval menstrual bleeding, PMB: postmenopausal bleeding, PCB: postcoital bleeding

Table 2. Different types of abnormal pap smears in the present study

Pathological Type	Frequency	Percent
Abnormal pap smear	59	40.9
ASCUS	28	19.2
HSIL	13	8.9
LSIL	9	6.2
AGC	4	2.7
ASCH	5	3.4

ASCUS: Atypical Squamous Cells of Undetermined Significance, HSIL: High-grade Squamous Intraepithelial Lesions, LSIL: Low-grade Squamous Intraepithelial Lesions, AGC: Atypical Glandular Cells, ASCH: Atypical Squamous Cells: cannot exclude High-grade squamous intraepithelial lesion

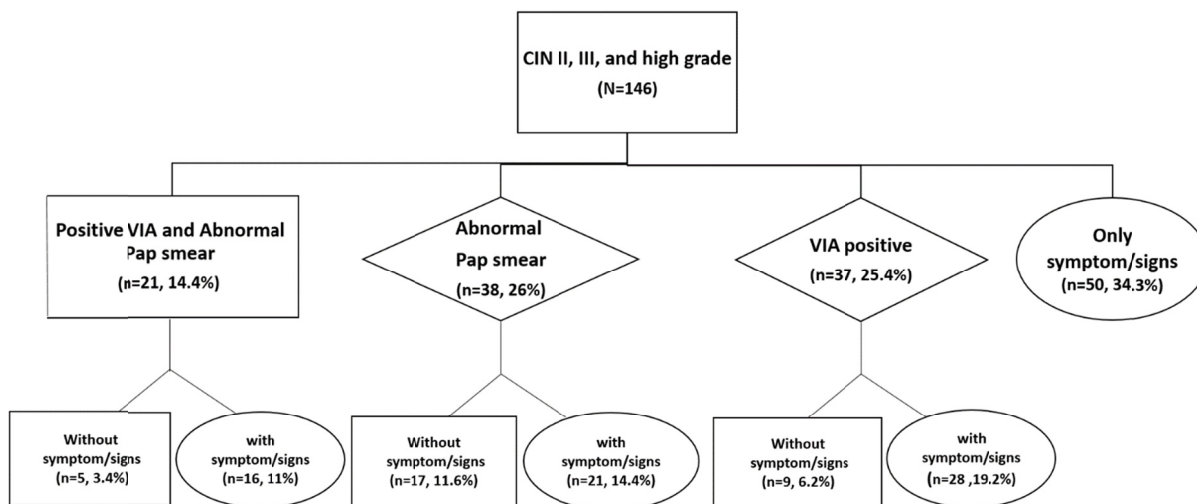


Fig. 2. Diagnosis algorithm of CIN II, III, and high-grade patients

Fifty patients (34.3%) were referred for colposcopy, only on the basis of having the described clinical symptoms/signs of the disease, leading to the diagnosis of CIN 2+ lesion (Fig. 2).

HPV testing was performed in only 37 patients, with 34 positive cases.

Overall, abnormal Pap smears were observed in 40.4% of patients and positive VIA was observed in 39.7% of patients. presence of at least one of the three clinical symptoms/signs and a positive VIA identified 78.8% of patients. The presence of at least one of the three clinical symptoms/signs and abnormal Pap smears identified in 84.2% of patients.

In summary, the sensitivity of VIA was found to be 73.39% (17.48%-83.31%), and that of Pap smear was 40.41% (32.47%-48.86%).

### Discussion

In the present study, the screening method was examined in 146 patients with high-grade cervical lesions. Similar to other studies, ASUC was the most common type of Pap smear abnormality.

In this study, the sensitivity of Pap smear in the finding of patients with CIN 2+ pathology was 40.4% and in this group, 21 patients also reported accompanying symptoms/signs (at least one of the: abnormal bleeding, vaginal discharge or an abnormal appearance of the cervix) besides abnormal pap smear.

A 2019 study in India reported pap smear to be 66.7% sensitive as a screening tool for detection of CIN II and higher lesions (13). Another similar study in Iran, conducted in 2011, reported Pap smear to be only 23% sensitive and 62% specific; similarly, in our study, we also found Pap smear to have low sensitivity (14).

VIA is a cost-effective alternative method of cervical screening in each level of health care settings. In this study, 39.7% of patients were positive when screened by this method. The sensitivity of VIA in our study was

estimated to be 73.39%.

In a study in China in 2001, VIA was reported to be 71% sensitive and 74% specific, which are comparable to the findings of our study (12). Therefore, as recommended by WHO, VIA testing along with Pap smears can be considered for use in cervical screening programs in developing areas.

In the present study, it was shown that in 50 patients (34.3%) colposcopy was done on the basis of the presence of one or more of the clinical symptoms/signs, namely: abnormal bleeding, chronic discharge and abnormal cervix shape, despite having normal screening test, ultimately leading to detection of high-grade lesion. This finding indicates the risk of false-negative results in the screening tests.

VIA and Pap smear, alone or in combination, detected 96 cases (65.7%), irrespective of the clinical findings. In the presence of at least one of three clinical symptoms/signs, the sensitivity of VIA increased to 78.8% and that of pap smear reached 84% for detection of high-grade cervical lesions. As is obvious, the addition of clinical symptoms/signs significantly increases the sensitivity of the screening tests and helps find more cervical pre-invasive lesions.

The addition of HPV testing to Pap smear as a CO-TEST increases the diagnostic accuracy for detection of high-grade intra-epithelial cervical lesions. In this study, HPV testing was performed in 37 patients and was positive for high-risk HPV in 34 patients. No statistically significant relationship was evident between the positivity of this test and the type of pathology. Due to the small number of cases tested for HPV, it was not possible to further evaluate this issue. Due to the high cost of HPV testing in Iran, and with regards to the results of our current study, focused attention should be paid to the clinical manifestations of cervical lesions, which can increase the sensitivity of Pap smear and VIA test in cervical screening.

In this study, it was not possible to determine the specificity of the tests due to the lack of a control group, and this is the limitation of our study. On the other hand, due to the retrospective nature of the study, confirmation of the results in future studies is suggested.

### Conclusion

Based on the results of this study, we concluded that in the screening of high-grade cervical lesions, attention to three clinical symptoms/signs (i.e., abnormal cervix, abnormal bleeding and chronic vaginal discharge), even in the presence of a normal Pap smear, is of great importance and by using these clinical symptoms/signs, we can increase the sensitivity of Pap smear and VIA test. HPV testing or colposcopy can be used as specific investigations to further evaluate these symptoms. Also, in centers with limited facilities, VIA, which is a simple and highly sensitive (73.3%) method, can be used to complement, or in some cases replace the other screening methods.

### Acknowledgment

We would like to thank the nursing, the administrative and secretarial staff of the obstetrics and gynecology department, and the Gyneco-Oncology clinic at Imam Hossein Medical center.

### Conflict of Interests

The authors declare that they have no competing interests.

### References

1. Naizhaer G, Yuan J, Mijiti P, Aierken K, Abulizi G, Qiao Y. Evaluation of multiple screening methods for cervical cancers in rural areas of Xinjiang, China. *Medicine*. 2020 Feb;99(6).
2. Shrestha AD, Neupane D, Vedsted P, Kallestrup P. Cervical cancer prevalence, incidence and mortality in low and middle income countries: a systematic review. *Asian Pac J Cancer Prev*. 2018;19(2):319.
3. Nakisige C, Trawin J, Mitchell-Foster S, Payne BA, Rawat A, Mithani N, et al. Integrated cervical cancer screening in Mayuge District Uganda (ASPIRE Mayuge): a pragmatic sequential cluster randomized trial protocol. *BMC Public Health*. 2020 Dec 1;20(1):142.
4. Arbyn M, Weiderpass E, Bruni L, de Sanjosé S, Saraiya M, Ferlay J, et al. Estimates of incidence and mortality of cervical cancer in 2018: a worldwide analysis. *Lancet Glob Health*. 2020 Feb 1;8(2):e191-203.
5. World Health Organization. Draft global strategy towards the elimination of cervical cancer as a public health problem. Available at <https://www.who.int/docs/default-source/cervical-cancer/cerv-cancer-elimn-strategy-16dec-12pm.pdf> (Dec 16, 2019), Accessed 28th Jan 2020
6. Taheri N, Fazel A, Mahmoodzadeh H, Omranpour R, Roshandel G, Gharahjeh S, et al. Epidemiology of female reproductive cancers in Iran: results of the Gholestan Population-based Cancer Registry. *Asian Pac J Cancer Prev*. 2014;15(20):8779-82.
7. Khorasanizadeh F, Hassanloo J, Khaksar N, Taheri SM, Marzaban M, Rashidi BH, et al. Epidemiology of cervical cancer and human papilloma virus infection among Iranian women—Analyses of national data and systematic review of the literature. *Gynecol Oncol*. 2013 Feb 1;128(2):277-81.
8. Berek JS, Novak E. Berek & Novak's Gynecology. Cervical and Vaginal Cancer. 16 ed. Philadelphia: Wolters Kluwer Health/Lippincott Williams & Wilkins; 2019. p. 2445-2540.
9. Berek JS, Novak E. Berek & Novak's Gynecology. Intraepithelial Disease of the Cervix, Vagina, and Vulva. 15 ed. Philadelphia: Wolters Kluwer Health/Lippincott Williams & Wilkins; 2012. p. 910-

- 967.
10. Gaffikin L, McGrath JA, Arbyn M, Blumenthal PD. Visual inspection with acetic acid as a cervical cancer test: accuracy validated using latent class analysis. *BMC Medical Res Methodol*. 2007 Dec 1;7(1):36.
11. Gad MM, Galal SB, Helmy W, Abd El-Fattah NH. Screening of Cervical Cancer: Visual Inspection with Acetic Acid (VIA) and Site of Lesion Verified by Multiple Punch Biopsies. *Folia Med*. 2019 Jun 1;61(2):289-95.
12. Belinson J, Qiao YL, Pretorius R, Zhang WH, Elson P, Li L, et al. Shanxi Province Cervical Cancer Screening Study: a cross-sectional comparative trial of multiple techniques to detect cervical neoplasia. *Gynecol Oncol*. 2001 Nov 1;83(2):439-44.
13. Mishra GA, Pimple SA, Gupta SD. Cervical Cancer screening in low resource settings: cytology versus HPV triage for VIA positive women. *Int J Prev Med*. 2019;10.
14. Khodakarami N, Farzaneh F, Aslani F, Alizadeh K. Comparison of Pap smear, visual inspection with acetic acid, and digital cervicography as cervical screening strategies. *Arch Gynecol Obstet*. 2011 Nov 1;284(5):1247-52.